



## INSECTS

Bee and wasp stings can be very serious and deadly if the dog goes into anaphylactic shock (as some people do). Dogs like to snap at small flying “things”, particularly puppies who think that chasing and catching these creatures is great fun. If stung inside the mouth or on the tongue or near the throat, swelling occurs, followed by suffocation. Again, if the dog is locked out, and the owner does not notice such accidents, the animals are beyond help.

## SWIMMING POOLS


Dogs do not need swimming lessons, they are natural swimmers. However, an “outdoor dog” may fall in or go in the water for a swim, becomes disoriented because no one taught him where the steps are or how find the shallow end. He will not be able to come out and he CANNOT float. He must paddle in order to keep his head above water and if he becomes exhausted, he will drown.

## PET THEFT

Pet theft is a fact of life and it is on the rise. The thieves are highly accomplished and fast. They will open gates, lift dogs over fences, lure them away and the reasons for stealing dogs (and cats) are many. Some are sold to experimenters, some used for breeding (please, spay and neuter your pets!), or for sale, and smaller dogs and cats are used as bait to train Pit Bulls to kill. This is truly a nasty underbelly of pet-life.

Dogs offer the priceless gifts of loyalty, steadfast devotion and reassuring, incomparable companionship. The back yard dog merely exists, becomes bewildered, emotionally injured and physically at risk – in short, he suffers. For both his and the owner’s sake, it would have been better not to get a dog or a cat in the first place.

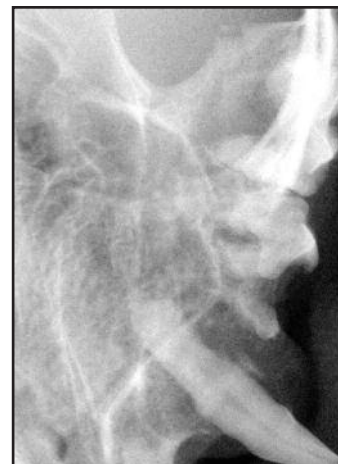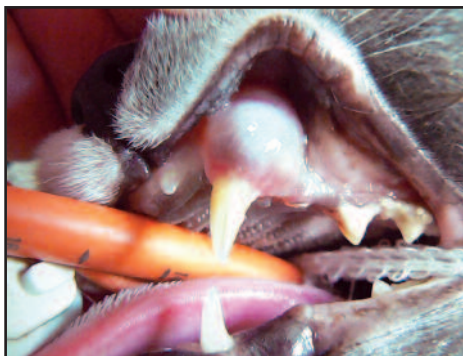NOTE: Please feel free to copy and give this to owners who have “yard dogs” or who are contemplating getting a dog who will not be allowed in the house.



# DIAGNOSTIC CHALLENGE

### History and Initial Exam:

A 10 year old cat presents with a left maxillary swelling. On examination, there is a 12-15 mm smooth swollen area of gingiva and buccal mucosa apical to the left maxillary canine tooth. The epithelium is intact without ulceration or bleeding and the area feels somewhat soft. The tooth crown is normal in appearance and has moderate mobility but no abnormal probing depths. See the dental x-ray. Make a list of several reasonable rule-outs and formulate a diagnostic plan.



*Answer on page 21*